

Experience With Drug-Eluting Technologies in BTK Interventions

Promising results for drug-eluting stent use in CLI patients with lesions below the knee.

BY HANS VAN OVERHAGEN, MD, PhD, EBIR



Critical limb ischemia (CLI) is the end stage of peripheral artery disease and represents a substantial burden for patients and health care systems due to its poor prognosis for both limbs and lives. Recanalization of occluded leg vessels remains the most effective therapy, since

medical treatment is not very effective and new cell therapies have been disappointing thus far. In the last decade, endovascular therapy has replaced vascular surgery as the recommended recanalization strategy. For lesions below the knee (BTK), the combination of percutaneous transluminal angioplasty (PTA) and bailout bare-metal stenting (BMS) is the standard endovascular treatment.¹ Although the initial technical success rate of PTA and bailout BMS is reported to be relatively high, long-term results are negatively affected by restenosis due to intimal hyperplasia.²

FINDINGS FROM RECENT STUDIES

Drug-eluting technologies have been used in BTK lesions in order to reduce restenosis rates after endovascular treatment. After an initial optimistic report, the results of drug-coated balloons (DCBs) BTK have been disappointing. In the IN.PACT DEEP trial, a randomized postmarket trial designed to assess the safety and efficacy of the paclitaxel-eluting In.Pact Amphirion DCB (Medtronic) compared with PTA within the CLI population, all lesion-specific primary and secondary endpoints showed insignificant differences between the two study arms. In addition, the DCB showed “a trend towards an increased major amputation rate through 12 months compared to PTA,” as noted by Zeller et al.³ The authors state that it can be hypothesized that potential disease, device, and/or procedural factors may have contributed to the observed lack of drug treatment effect; that the 2.4-fold higher major amputation rate is perplexing; and that these negative results are contrary

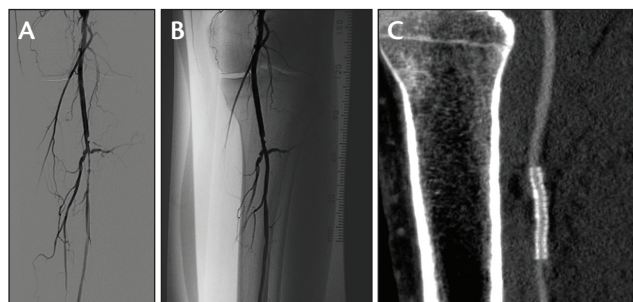


Figure 1. Stenosis of peroneal artery in a patient with CLI (A). Results after DES implantation (B). CTA at 6-month follow-up (C).

to the results of the In.Pact DCB and others in the femoropopliteal arteries.³

Regarding the morphology of stenotic and occluded BTK arteries in CLI, one may hypothesize that the drug is rubbed off the balloons during passage through the long, narrow, and calcified tract toward the crural arteries, and thus diminished local effectiveness and distal embolization result. Mounting polymer and drug to a stent may result in a more fixed coating with better-controlled release of the drug without particle embolization. In the IDEAS randomized controlled trial that compared paclitaxel-coated DCBs with drug-eluting stents (DESs) in long (≥ 70 mm) infrapopliteal lesions, DESs demonstrated significantly lower residual postprocedure stenosis and significantly reduced restenosis at 6 months.⁴ Results of DES BTK in general have been more encouraging morphologically regarding restenosis rates, but until recently, clinical data were lacking.⁵ This may be at least partially caused by the fact that many DES BTK studies have included patients with intermittent claudication who are unlikely to reach hard clinical endpoints, such as amputation or death, as well as the limited numbers of patients in the studies.

In the PTA and DES for Infrapopliteal Lesions in Critical Limb Ischemia (PADI) trial, patients with CLI (Rutherford

category ≥ 4) were randomized to undergo treatment with either PTA \pm BMS or a paclitaxel DES (Taxus Liberté, Boston Scientific Corporation). The primary endpoint was 6-month primary binary patency of the treated lesions, defined as $\leq 50\%$ stenosis on CTA (Figure 1). Stenosis $> 50\%$, retreatment, major amputation, and CLI-related death were regarded as treatment failure. The severity of failure was assessed with an ordinal score, ranging from vessel stenosis through occlusion to clinical failures.⁶

Six-month patency rates were 48% for the DES arm and 35.1% for the PTA \pm BMS arm ($P = .096$) in the modified intention-to-treat population and 51.9% and 35.1% ($P = .037$), respectively, in the per-protocol analysis. The ordinal score showed significantly worse treatment failure for PTA \pm BMS versus DES ($P = .041$). The observed major amputation rate remained lower in the DES group until 2 years posttreatment, with a trend toward significance ($P = .066$). Fewer minor amputations occurred in the DES arm through 6 months posttreatment ($P = .03$).⁷

Long-term follow-up of the PADI trial consisted of annual assessments up to 5 years posttreatment or until a clinical endpoint was reached. Preserved primary patency ($\leq 50\%$ restenosis) of treated lesions was an additional morphological endpoint assessed by duplex ultrasound. The estimated 5-year major amputation rate was lower in the DES arm (DES, 19.3% vs PTA \pm BMS, 34%; $P = .091$). The 5-year amputation-free survival and event-free survival (survival free from major amputation and reintervention) rates were significantly higher in the DES arm (DES, 31.8% vs PTA \pm BMS, 20.4%; $P = .043$; and DES, 26.2% vs PTA \pm BMS, 15.3%; $P = .041$, respectively). Survival at 5 years (52%–56%) was comparable for both groups. The limited available morphologic results showed higher preserved patency rates with the DES than after PTA \pm BMS at 1, 3, and 4 years of follow-up.⁸

CONCLUSION

Currently available data on DCBs BTK are disappointing, whereas the results of DESs BTK in those with CLI seem promising. The long-term follow-up results from PADI show that survival rates at 5 years in patients with CLI are around 50%, which suggests that the “leave nothing behind” approach may not be the only treatment pathway to be followed in CLI patients who require BTK treatment. Because DESs, at present, are of limited length and patients with CLI are known to have long lesions, the development of a long, self-expandable DES seems warranted. ■

1. Van Overhagen H, Spiliopoulos S, Tsetis D. Below-the-knee interventions. *Cardiovasc Intervent Radiol*. 2013;36:302–311.
2. Mustapha JA, Finton SM, Diaz-Sandoval LJ, et al. Percutaneous transluminal angioplasty in patients with infrapopliteal arterial disease: systematic review and meta-analysis. *Circ Cardiovasc Interv*. 2016;9:e003468.
3. Zeller T, Baumgartner I, Scheinert D, et al; for the IN.PACT DEEP Trial Investigators. Drug-eluting balloon versus standard balloon angioplasty for infrapopliteal arterial revascularization in critical limb ischemia: 12 month results from the IN.PACT DEEP randomized trial. *J Am Coll Cardiol*. 2014;64:1568–1576.
4. Siablis D, Kitrou PM, Spiliopoulos S, et al. Paclitaxel-coated balloon angioplasty versus drug-eluting stenting for the treatment of infrapopliteal long-segment arterial occlusive disease: the IDEAS randomized controlled trial. *JACC Cardiovasc Interv*. 2014;7:1048–1056.
5. Katsanos K, Spiliopoulos S, Diamantopoulos A, et al. Systematic review of infrapopliteal drug-eluting stents: a meta-analysis of randomized controlled trials. *Cardiovasc Intervent Radiol*. 2013;36:645–658.
6. Martens JM, Knippenberg B, Vos JA, et al. Update on PADI trial: percutaneous transluminal angioplasty and drug-eluting stents for infrapopliteal lesions in critical limb ischemia. *J Vasc Surg*. 2009;50:687–689.
7. Spreen MJ, Martens JM, Hansen BE, et al. Percutaneous transluminal angioplasty and drug-eluting stents for infrapopliteal lesions in CLI (PADI) trial. *Circ Cardiovasc Interv*. 2016;9:e002376.
8. Spreen MJ, Martens JM, Knippenberg B, et al. Long-term follow-up of PADI trial: percutaneous transluminal angioplasty versus drug-eluting stents for infrapopliteal lesions in critical limb ischemia. *J Am Heart Assoc*. 2017;6:e004877.

Hans van Overhagen, MD, PhD, EBIR

Department of Radiology
Haga Teaching Hospital
The Hague, The Netherlands
h.voverhagen@hagaziekenhuis.nl

Disclosures: Consultant to Boston Scientific Corporation.